

Indian Journal of Modern Research and Reviews

This Journal is a member of the 'Committee on Publication Ethics'

Online ISSN: 2584-184X



Research Article

Was Ravana a Craniopagus?

Anustup Datta and Atindra Nath Datta

DOI: <https://doi.org/10.5281/zenodo.11004060>

Abstract:

In Hindu mythology Ravana, the king of Sri Lanka supposed to possess ten heads. Physically it was impossible to carry ten heads on a single neck and ten brains to be supplied with a single heart. Brains cannot live or work without sensory and motor nerves. Therefore, the concept of ten heads is illusion. Functionally Ravana was a sane person and skilled warrior and possessed no double personality or more. So why Ravana was attributed with ten heads? As discovered from Google search two faces possessed with double noses, eyes could be more and ear abnormalities are common, it is deduced that Ravana was having multiple ears, eye and noses planted on a single cranium as if conceptualized as fused ten heads (craniopagus).

Keywords: Ravana, Craniopagus, multiple noses.

Introduction

In Hindu mythology there was a king (Ravana) in Sri Lanka who happened to possess ten heads fused into a single mass called craniopagus. In embryological reports, no such descriptions cited in literature, neither there was any vivid descriptions of how many eyes, ears or noses were there in addition to ten heads. Body was one and he was a skilled fighter. There are reports of craniopagus where bodies are separated with their independent thinking abilities and unfortunately, they die during head separation operation.

This type of craniopagus with existing whole body parts is not the same as was described in RAMAYANA (Hindu mythology). Description of Ravana as picturized in Delhi Ram lila maidan during Dussehra festival (**Pic. 4**) does not symmetrically attached with body. Means there was no clear concept of making a body to be attached with ten heads. Even anatomically, it is hard to conceptualise a single heart machine can irrigate ten brains simultaneously and so smoothly, that he can skillfully fight with another skilled opponent.

This brings us to a concept that Ravana's craniopagus is quite different. It may be a single mass of head where brain may be single and encased within a single cranium but there may be multiple eyes, ears and noses (**Pic. 1,2,3**). Suspicion of craniopagus theory came to our mind that multiplicity of eyes, ears and noses are in the literature (especially third eye in Hindu mythology). How people concepted 10 heads on a neck of a person when it is anatomically impossible. A narrow neck cannot hold the weight of ten heads, nor can a single heart irrigate ten brains. Brains will be defunct if there were no existant cranial nerves, spinal cord with its sensory and motor nerves. So the theory of merging of ten heads is nothing of ten craniums but existence of multiplicity of eyes, ears or noses attached on a single cranium

Article History

- ISSN: 2584-184X
- Received: 17 Feb 2024
- Accepted: 29 Mar 2024
- Published: 20 Apr 2024
- MRR:2(4) Apr. 2024: 01-03
- ©2024, All Rights Reserved
- Peer Review Process: Yes
- Plagiarism Checked: Yes

Authors Details

Anustup Datta (MD Medicine)
Assistant Professor of Medicine,
Washington University of
Barbados, West Indies

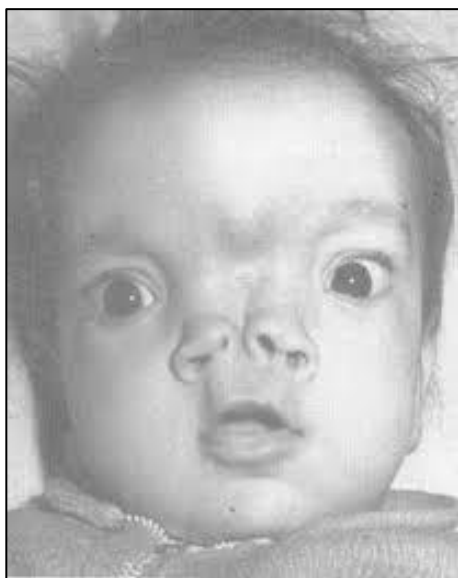Anustup Datta (MBBS, MS)
Professor of Anatomy,
Washington University of
Barbados, West Indies

Corresponding Author

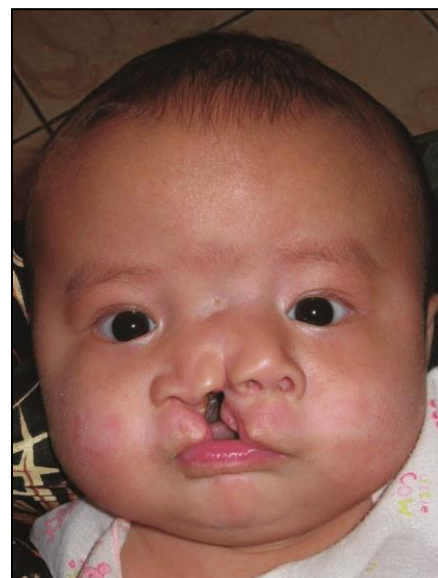
Anustup Datta (MBBS, MS)
Professor of Anatomy,
Washington University of
Barbados, West Indies

After fertilization occurs the zygote, undergo multiple divisions until 8-cell stage, called morula. It is encapsulated within a very strong capsule called zona pellucida. These to form 8 complete embryos. So far, the world newspaper reports octaplets were delivered successfully. There is no further number of twins reported to be delivered. In the embryology, after morula formation, the zona pellucida breaks and uterine fluid trickles inside zonal cavity and morula cease to exist and blastocyst starts. Now outer cells will go into formation of placenta while central

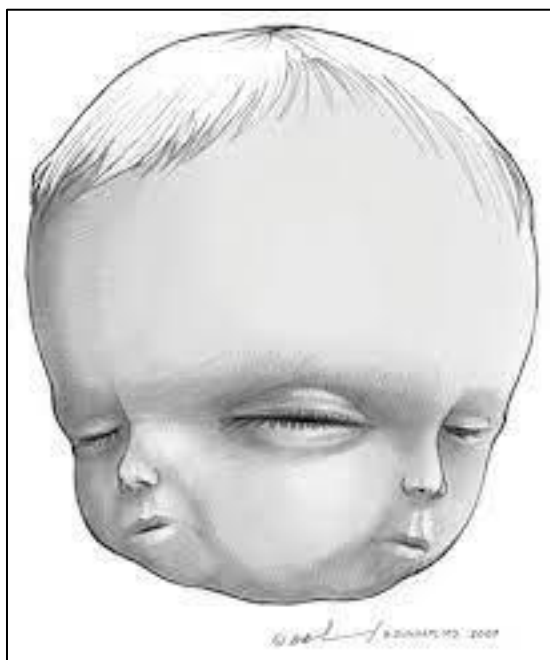cells will be called Inner Cell Mass (ICM) and this will go into formation of fetus or fetu. By 12-post fertilization day, ICM must come out of zona pellucida shell and there will be a single embryo. If the consistency of zona pellucidal wall is hard nut to crack there is high chance of making thoracopagus, omphalopagus, craniopagus etc, because ICM will struggle to emerge out of a narrow crack of zona pellucida and by sudden jerk ICM may split 2-8 fragments or monozygotic twins (as reported in newspapers).



Picture 1: Double noses in a single face (Google scholar)



Picture 2: Double noses with cleft lip in a single face (Google scholar)



Picture 3: Rizzi and Durham 2013 have conceptualized an imaginary illustration



Picture 4: This is the effigy of Ravana displayed in Delhi Ramlila maidan before burning at the end of Dusserah festival where a central head is idealized and other nine heads are being attached with no justification of anatomy knowledge.

Discussion

This example was used to describe more than one head. Here it is two but in case of Ravana there were ten heads conceptualized. Anatomically ten separate full blown heads placed on neck and supplied by a single heart is no longer tenable. So far is the description in the mythology, Ravana was a sane personality and no evidence of double, triple or ten personality human being. It indicates he had single cranium with a single brain but attached with multiple eyes, ears and noses. As we cite pictures from Google scholar, two faces with double noses jumping to common perception of persons that it is a case of fused double heads (craniopagus). Though once in billion, similar multiple eyes/ears/noses existed on a single head and a wrong conclusion was drawn that ten heads are fused on a single cranium resulted in Ramayan epic's counter hero named Ravana as Dasanan (ten heads fused).

REFERENCE

1. Mark D Rizzi and Brian P Durham: Congenital malformations of the nose and nasopharynx. Chapter one , First online January 1,2013. [[PubMed](#)] [[CrossRef](#)] [[Google Scholar](#)]
2. Deshpande SN. Congenital duplication of nostril. Indian J Plast Surg. 1995;28:39–41. [[Google Scholar](#)]
3. Hallak A, Jamjoom H, Hosseinzadeh T. Supernumerary nostrils: A case report and review. Aesthetic Plast Surg. 2001;25:241–3. [[PubMed](#)] [[Google Scholar](#)]

Creative Commons (CC) License

This article is an open access article distributed under the terms and conditions of the Creative Commons Attribution (CC BY 4.0) license. This license permits unrestricted use, distribution, and reproduction in any medium, provided the original author and source are credited.